Ischemic Colitis
key histologic feature

MD.Mona.Akbari

Pathologist AP/CP

GI and Liver Pathology Fellowship

TABLE 17.9 Patterns of Ischemic Colitis

Pattern	Symptoms and Signs	Pathogenesis/Etiology	Key Histological Features	Outcome
Acute transient (reversible) ischemic colitis	Sudden-onset abdominal cramping, diarrhea, passage of blood within 24 hours after onset of symptoms	Nonocclusive ischemia: low flow state (vascular hypoperfusion, vasospasm associated with medications, infections (see Box 17.7) Sudden embolic event	1-2 hours: mucosal and submucosal edema, hemorrhage, and surface epithelial detachment Reperfusion causes neutrophilic inflammatory infiltrates and cryptitis	Symptoms typically resolve with conservative measures without long-term sequelae
Acute severe (irreversible) ischemic colitis	Early stage: sudden-onset severe abdominal pain, bloody diarrhea Late stage: diffuse and continuous abdominal pain with tenderness	Occlusive ischemia • Arterial and venous thrombosis, vasculitis, small and medium vessel disorders (amyloidosis, diabetes mellitus, radiation) • Hypercoagulable states • Obstruction (colon cancer, strictures, adhesions, volvulus, hernia)Infections: *Escherichia coli*	Early phase: mucosal erosions, ulceration and necrosis, lamina propria hemorrhage, "withered crypts," lamina propria hyalinization Late phase: transmural necrosis, extensive bowel wall edema, serositis	20% of patients require surgical resection Despite surgery, mortality is 60%
Chronic recurrent ischemic colitis	Persistent bloody diarrhea With symptomatic stricture: nausea, vomiting, sepsis	Occlusive ischemia caused by slow-growing atheromatous plaques in mesenteric blood vessels	Mucosal erosions with granulation tissue formation, hemosiderin, and submucosal and/or mural fibrosis	Segmental resection is the choice of therapy; recurrence occurs in 5% of patients

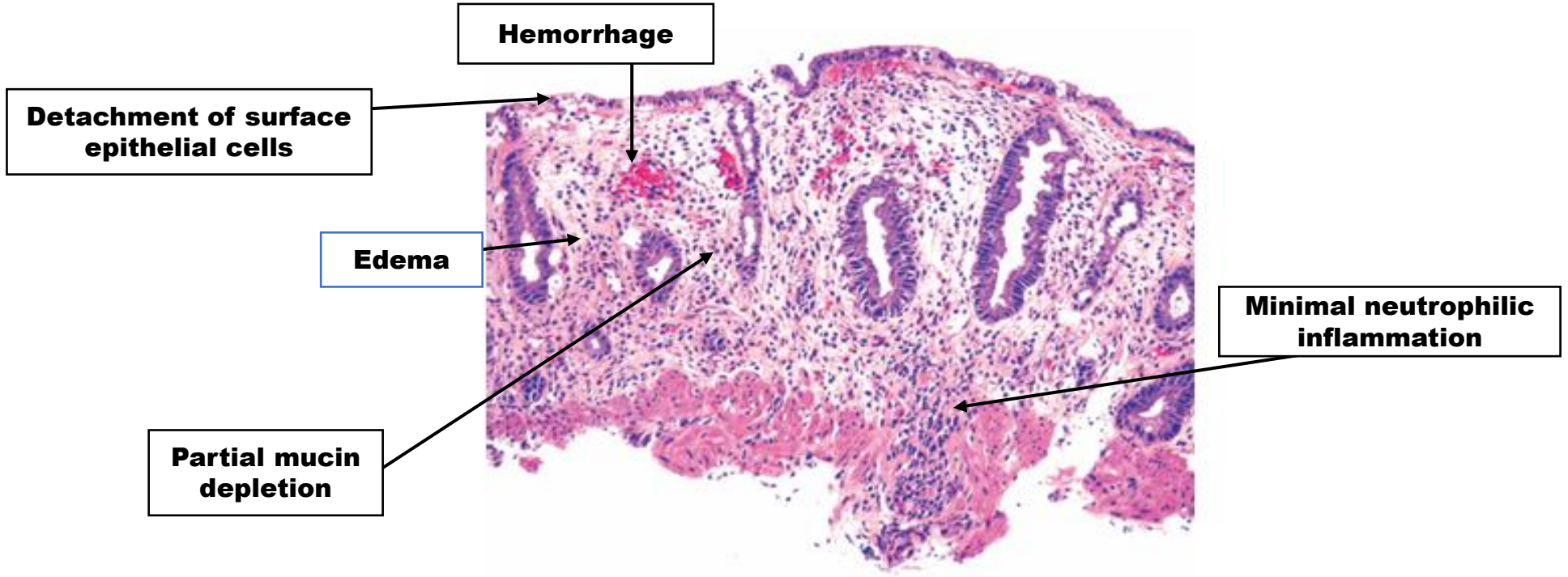
Hemorrhage
Detachment of surface epithelial cells
Edema
Partial mucin depletion
Minimal neutrophilic inflammation

Superficial mucosal erosion

Hyalinized appearance

Withered atrophic crypts

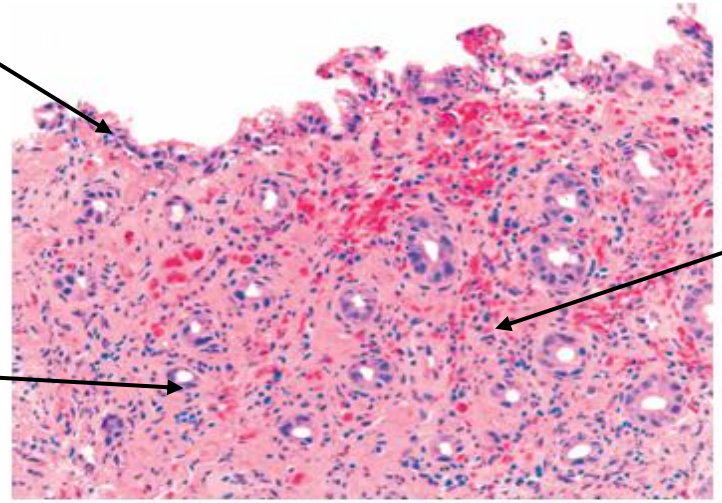

Capillary microthrombi

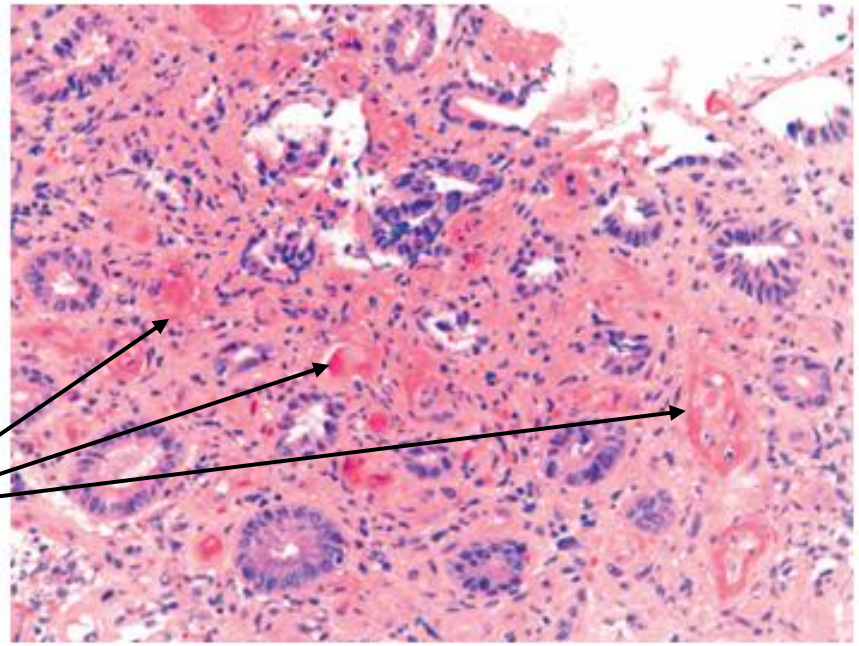

degenerating surface epithelial cells slough off into the crypt lumen and acquire a signet ring cell appearance

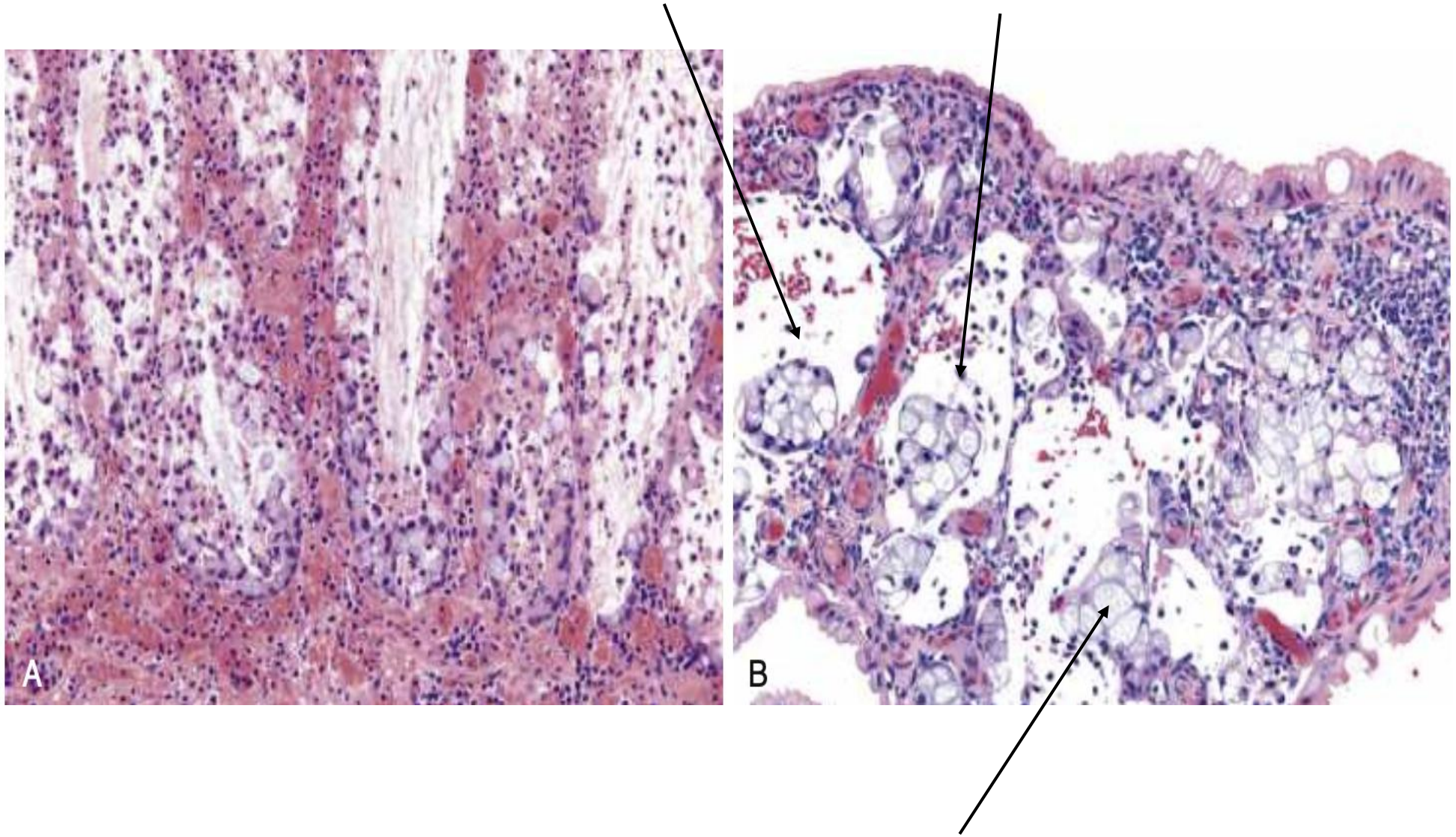

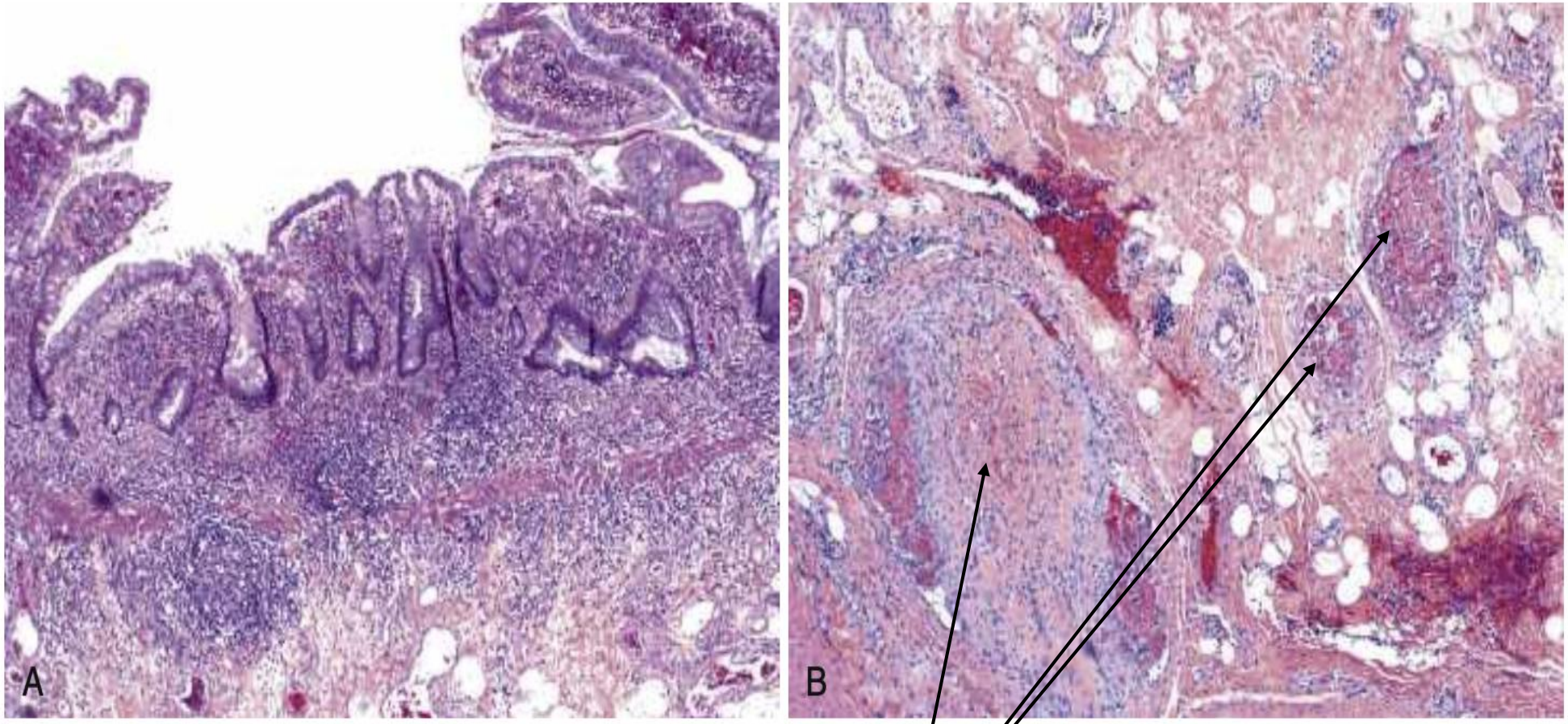

Organizing thrombi within the pericolonic blood vessels

FEATURES OF ACTIVITY

Neutrophilic (or eosinophilic) cryptitis
Crypt abscesses
Necrosis
Regenerative and degenerative epithelial changes
Erosions
Ulcers

FEATURES OF CHRONICITY

Crypt architectural distortion
- Crypt atrophy
- Crypt foreshortening
- Irregular spacing of crypts
- Irregular size of crypts
- Crypt branching or budding
- Loss of crypt parallelism
- Villiform surface contour

Basal plasmacytosis
Basal lymphoid aggregates
Diffuse mixed lymphoplasmacytic infiltrate within the lamina propria
Paneth cell metaplasia in the left colon (hyperplasia in the right colon)
Pyloric gland metaplasia
Lamina propria or submucosal fibrosis
Thickening or duplication of the muscularis mucosae

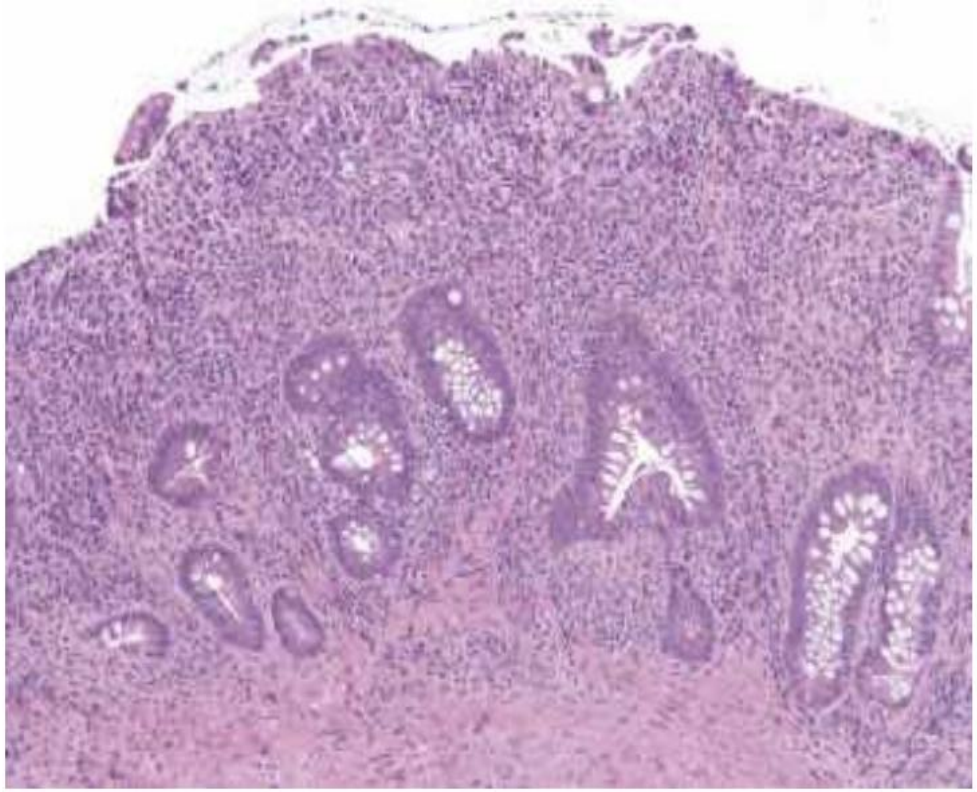

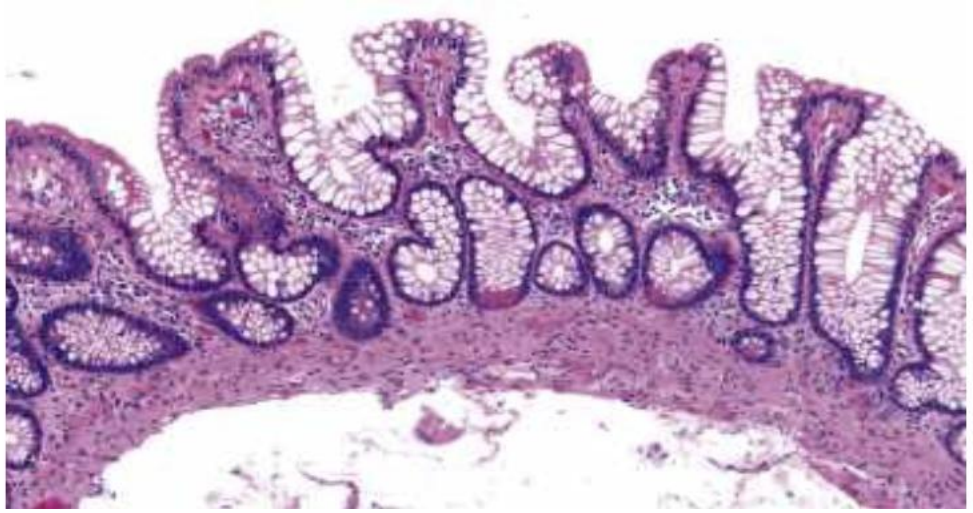

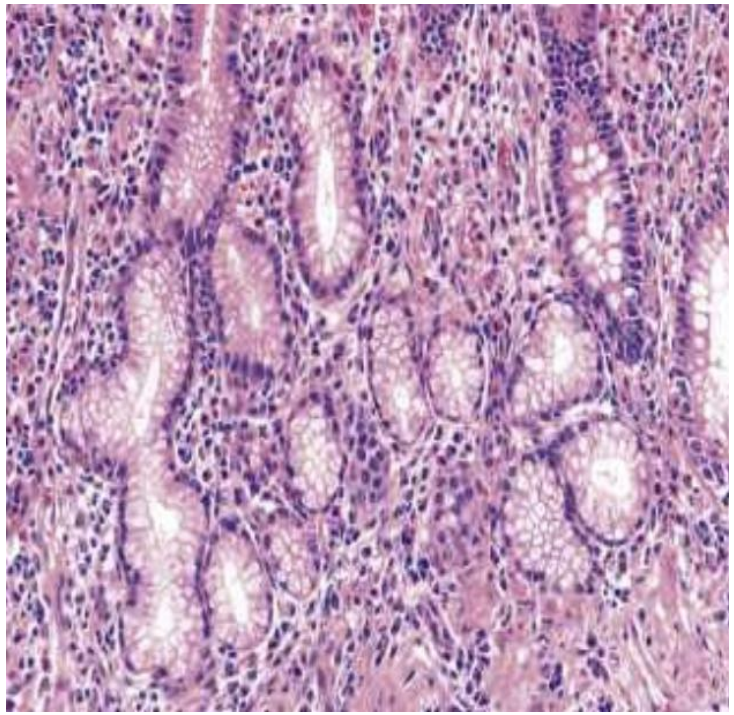

Ischemic Colitis vs IBD – Histologic Differential

ISCHEMIC COLITIS (Acute/Chronic)

1. **Withered crypts**
   - Shrinkage/angulation
   - Loss of regenerative activity
2. **Lamina propria hyalinization**
   - Eosinophilic, glassy stromal change
   - Most helpful clue for ischemia
3. **Hemorrhage/ congestion**
   - Extravasated RBCs
   - Dilated congested vessels
4. **Surface epithelial injury**
   - Attenuation / erosion
   - Early necrosis

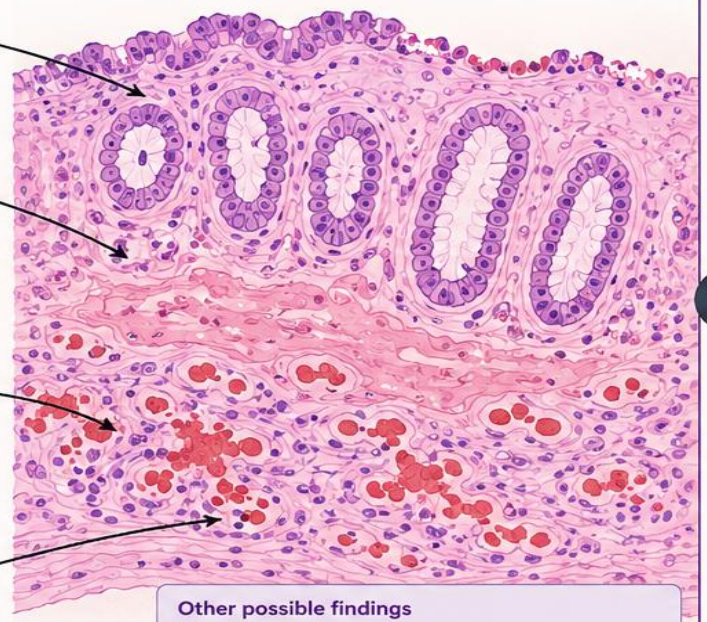

Other possible findings
- Mucosal edema
- Pseudomembrane (in severe cases)
- Coagulative necrosis (in severe ischemia)

VS

IBD (Ulcerative Colitis / Crohn Disease)

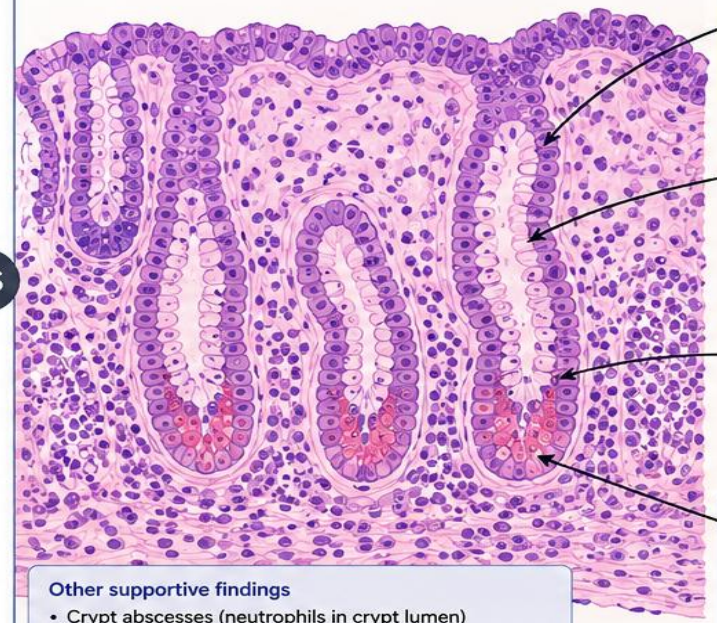

1. **Basal plasmacytosis**
   - Plasma cells in the basal lamina propria
   - Characteristic of IBD
2. **Crypt architectural distortion**
   - Branching, shortening, irregular spacing
   - Loss of parallel alignment
3. **Paneth cell metaplasia**
   - Paneth cells in left colon in longstanding disease
4. **Chronic inflammatory infiltrate**
   - Lymphocytes, plasma cells, eosinophils
   - Diffuse and prominent

Other supportive findings
- Crypt abscesses (neutrophils in crypt lumen)
- Granulomas (in Crohn disease)
- Ulceration with chronic inflammatory base

CLINICOPATHOLOGIC CLUES

- Older age, vascular risk factors
- Sudden onset, abdominal pain, bloody diarrhea
- Watershed distribution (splenic flexure, rectosigmoid)
- History of hypotension, shock, or vascular disease

FEATURE	ISCHEMIC COLITIS	IBD
Crypt architecture	Preserved early; mild distortion later	Marked distortion (chronic)
Basal plasmacytosis	Absent	Present
Lamina propria hyalinization	Present (key feature)	Absent
Withered crypts	Present	Uncommon
Hemorrhage / congestion	Prominent	Usually mild
Chronic inflammation	Mild or secondary	Prominent and diffuse
Paneth cell metaplasia	Rare	Common in longstanding disease
Granulomas	Absent	May be present (Crohn)

KEY TAKE-HOME MESSAGE

★ Withered crypts + Lamina propria hyalinization + Hemorrhage = Think **Ischemia**

★ Basal plasmacytosis + Crypt distortion + Paneth cell metaplasia = Think **IBD**